

Published in final edited form as:

*Diagn Imaging Eur.* 2013 January ; 29(1): 12–15.

## PET-directed, 3D Ultrasound-guided prostate biopsy

**Baowei Fei,**

Department of Radiology and Imaging Sciences, Emory University, 1841 Clifton Road NE,  
Atlanta, GA 30329, USA

**Peter T Nieh,**

Department of Urology, Emory University, 1365 Clifton Road NE, Atlanta, GA 30322

**David M Schuster,** and

Department of Radiology and Imaging Sciences, Emory University, 1841 Clifton Road NE, Atlanta,  
GA 30329

**Viraj A Master**

Department of Urology, Emory University, 1365 Clifton Road NE, Atlanta, GA 30322

Baowei Fei: baowei.fei@emory.edu

### Abstract

Multimodality imaging is a promising approach for improving prostate cancer detection and diagnosis. This article describes various concepts in PET-directed, ultrasound-guided biopsies and highlights a new PET/ultrasound fusion targeted biopsy system for prostate cancer detection.

One in six men will be diagnosed with cancer of the prostate during their lifetime [1]. Systematic transrectal ultrasound (TRUS)-guided prostate biopsy is considered to be the standard method for prostate cancer detection. However current biopsy techniques have a significant sampling error, low sensitivity (27%–40.3%) and can miss up to 30% of cancers [2, 3]. As a result, a patient who has been informed of a negative biopsy result may in fact be harboring an occult early-stage cancer. It is a difficult challenge for physicians to manage such patients with false negative biopsies who in fact harbor curable prostate cancer as indicated by biochemical measurements such as rising prostate specific antigen (PSA), as well as patients diagnosed with early-stage disease. In many men, current diagnostic procedures are insufficient to distinguish aggressive prostate cancer, which requires treatment, from the non-aggressive form of disease, which can be well-managed with active surveillance.

Since the current standard of care practice for an initial prostate biopsy has a low cancer detection rate, the development and evaluation of new biopsy technologies is an active research area. MR/ultrasound fusion guided biopsy represents one approach. It has been reported that MR/TRUS fusion biopsy detects more cancer per core than standard 12-core TRUS biopsy for suspicion on MRI [2]. The use of three-dimensional (3D) tracking and image fusion has the potential to improve current methods for diagnosis and follow-up of prostate cancer [4].

PET imaging can detect metabolic and functional information of cancer. PET imaging agents such as  $^{11}\text{C}$ -choline [5, 6] have been developed for prostate cancer detection and staging. In particular, PET imaging with new molecular imaging tracers such as anti-1-aminio-3- $^{18}\text{F}$ -fluorocyclobutane-1-carboxylic acid ( $^{18}\text{F}$ -FACBC) has shown promising results for detecting and localizing prostate cancer in humans [7, 8]. PET/CT with  $^{18}\text{F}$ -FACBC show focal uptake at the tumor and thus can provide location information to direct targeted biopsy of the prostate. By combining PET/CT with 3D ultrasound images, multimodality image-guided targeted biopsy has become a promising technology for improved detection and diagnosis of prostate cancer [9].

## PET/ULTRASOUND FUSION TARGETED BIOPSY

Figure 1 shows the principles of the PET-directed, 3D ultrasound-guided biopsy. The system uses: (i) Passive mechanical components for guiding, tracking, and stabilizing the position of a commercially available, end-firing, transrectal ultrasound probe. (ii) Software components for acquiring, storing, and reconstructing in real-time a series of 2D TRUS images into a 3D image; and (iii) Other software that segments the prostate in 3D TRUS images and displays a model of the 3D scene to guide a biopsy needle in three dimensions. The system allows real-time tracking and recording of the 3D position and orientation of the biopsy needle as a physician manipulates the ultrasound transducer. An offline workstation system is used to register and fuse PET/CT and ultrasound images.

## WORKFLOW

The protocol for PET/CT directed, 3D ultrasound-guided biopsy of the prostate is as follows, (i) Before undergoing prostate biopsy, the patient undergoes a PET/CT scan. The anatomic CT images are combined with the PET images for improved localization of the prostate and suspicious tumors. (ii) The patient has a 3D ultrasound scan before the actual biopsy appointment. This ultrasound image is called “pre-biopsy” image and can be carried out one week before the biopsy or on the same day as the PET/CT scan, (iii) The PET/CT and pre-biopsy ultrasound images are registered offline before biopsy. (iv) Immediately before biopsy, another 3D ultrasound image volume is acquired before the biopsy planning. The “intra-biopsy” ultrasound images are registered with the pre-biopsy ultrasound images. As the pre-biopsy ultrasound image has been registered with the PET/CT data, the PET/CT image is, in turn, also registered with the intra-biopsy ultrasound image for tumor targeting. Three-dimensional visualization tools are then used to guide the biopsy needle to a suspicious lesion. (v) At the end of each core biopsy, the position of the needle tip is recorded on real-time ultrasound images during the procedure. The location information of biopsy cores is saved and can be restored in any re-biopsy procedure when the patient is followed up for prostate cancer examination. This allows the physician to re-biopsy the same area and check the possible progression or regression of a lesion. The information on the location of the biopsy cores can also be used to guide any other additional biopsy to different locations if the original biopsy was negative.

## AUTOMATIC SEGMENTATION AND DEFORMABLE REGISTRATION

In the use of 3D models to guide the biopsy, segmentation of the prostate is a key component of the overall 3D ultrasound image-guided biopsy technology. However, segmentation of the prostate can be difficult in ultrasound images because of the shadows from the bladder and because of low contrast between the prostate and non-prostate tissue.

We have developed an automatic method to segment the prostate in 3D TRUS images [10]. The method uses a wavelet-based texture extraction technique followed by support vector machines (SVMs) to adaptively collect texture priors of prostates and non-prostate tissues. Tissues in different sub-legions around the prostate boundary are then classified by statistically analyzing their textures using wavelet features [10]. Figure 3 shows the 3D prostate after segmentation.

In the incorporation of PET/CT into the 3D ultrasound-guided biopsy, image registration plays a key role in combining the two imaging multimodalities. However, deformable registration of ultrasound and PET/CT images is difficult for the several reasons, (i) Neither PET nor ultrasound has enough structural information on the prostate for direct intensity-based image registration, (ii) Ultrasound provides only a small field of view that covers just the prostate and surrounding tissue. This is only a small portion of a typical PET image that includes the entire pelvic region. (iii) The significant prostate deformation caused by the transrectal probe disqualifies registration algorithms that assume small deformation. We used CT images as the bridge to register PET with TRUS because both PET and CT images are acquired from a combined PET/CT system. We developed and evaluate a non-rigid registration method for this particular application [11]. Briefly, the registration method is a hybrid approach that simultaneously optimizes the similarities from point-based registration and volume matching methods. The 3D registration is obtained by minimizing the distances of corresponding points at the surface and within the prostate and by maximizing the overlap ratio of the bladder neck on both images. The hybrid approach not only capture deformation at the prostate surface and internal landmarks but also the deformation at the bladder neck regions.

## DISCUSSION AND CONCLUSION

We developed a molecular image-directed, 3D ultrasound-guided biopsy system for the prostate. The PET/ultra-sound fusion targeted biopsy technology can have an immediate impact on patient care. Several groups of patients could benefit.

- i. For patients who select active surveillance i.e. watchful waiting and whose biopsy result shows a low-grade, non-clinically significant tumor, an accurate biopsy can help to reduce their anxiety that is often increased by worry over possible sampling error and the uncertainty associated with the current biopsy technique. As a false negative result may delay treatment, an accurate biopsy is extremely important for such active surveillance patients because they rely on the biopsy result in order to follow up the disease without any radical treatment.

- ii. For patients diagnosed on biopsy as having premalignant lesions i.e. high grade prostatic intraepithelial neoplasia, and, in particular, atypical small acinar proliferation (ASAP), the biopsy result is clinically significant as there is a 40%–80% chance of finding cancer on repeat biopsy if there is ASAP [12]. As there might be coexisting cancer, especially with ASAP, where the pathologist finds only a small amount of histological “atypia” but not enough tissue to confidently diagnose cancer, such patients require a repeat biopsy soon after the first one. For ASAP patients, it is vital to rebiopsy the same area. Unfortunately, 2D ultrasound provides only a vague location of the abnormal findings, and it is not possible to be certain that the same area has been sampled by the repeat biopsy. The 3D ultrasound image-guided biopsy system is able to record the 3D location of the biopsy sites for follow-up examinations and thus has the potential to change the management of these ASAP patients.
- iii. If the targeted biopsy improves cancer detection rate, many patients would not need repeated biopsies, so the total number of prostate biopsies could be reduced. In addition this could also reduce the risk of life-threatening sepsis and transrectal bleeding, both of which are associated with biopsy procedures. The use of PET/ultrasound fusion targeted biopsies within the diagnostic pathway would thus result in an enhanced detection of clinically significant disease, with fewer men being diagnosed with clinically insignificant disease, fewer men being biopsied overall, and fewer needle deployments.

All this, could transform prostate cancer management and change current clinical practice from “blind” to “targeted” biopsy.

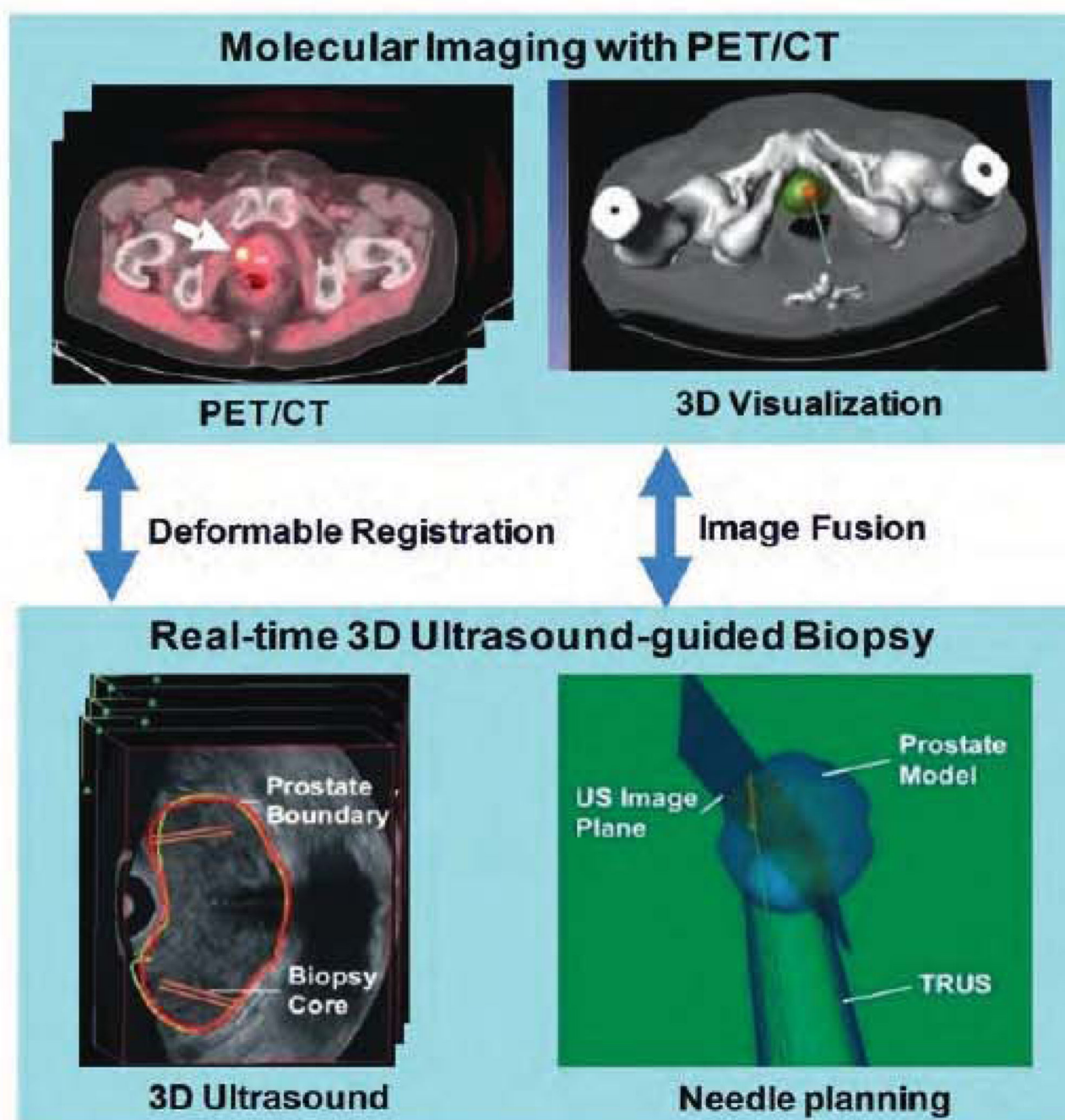
## Acknowledgments

This research is supported in part by NIH grants (R01CA156775 and P50CA128301) and Georgia Cancer Coalition Distinguished Clinicians and Scientists Award.

## REFERENCES

1. Howlader, N., et al. Bethesda, MD: National Cancer Institute; 2012. SEER Cancer Statistics Review, 1975–2009 (Vintage 2009 Populations). [http://seer.cancer.gov/csr/1975\\_2009\\_pops09](http://seer.cancer.gov/csr/1975_2009_pops09)
2. Pinto PA, et al. Magnetic resonance imaging/ultrasound fusion guided prostate biopsy improves cancer detection following transrectal ultrasound biopsy and correlates with multiparametric magnetic resonance imaging. *J Urol.* 2011; 166:1281. [PubMed: 21849184]
3. Hricak H. MR imaging and MR spectroscopic imaging in the pre-treatment evaluation of prostate cancer. *Br J Radiol.* 2005; 78:S103. [PubMed: 16306632]
4. Natarajan S, et al. Clinical application of a 3D ultrasound-guided prostate biopsy system. *Urol Oncol.* 2011; 29:334. [PubMed: 21555104]
5. Schilling D, et al. Histological verification of <sup>11</sup>C-choline-positron emission/computed tomography-positive lymph nodes in patients with bio-chemical failure after treatment for localized prostate cancer. *BJU Int.* 2008; 102:446. [PubMed: 18410442]
6. Fei BW, et al. Choline PET for monitoring early tumor response to photodynamic therapy. *J Nucl Med.* 2010; 51:130. [PubMed: 20008981]
7. Schuster DM, et al. Initial experience with the radiotracer anti-1-amino-3-F-18-fluorocyclobutane-1-carboxylic acid with PET/CT in prostate carcinoma. *J Nuclear Med.* 2007; 48:56.

8. Schuster DM, et al. Characterization of primary prostate carcinoma by anti-1-amino-2-[18F]-fluorocyclobutane-1-carboxylic acid (anti-3-[18F] FACBC) uptake. *American Journal of Nuclear Medicine and Molecular imaging*. 2013; 3:85. [PubMed: 23342303]
9. Fei, BW., et al., editors. A PET/CT directed, 3D ultrasound-guided biopsy system for prostate cancer; Workshop on Prostate Cancer Imaging. Annual Meeting of the Soc. of Med. Imaging Computing and Image Assisted Interventions (MICCAI), Lecture Notes in Computer Science; 2011.
10. Akbari H, Fei BW. 3D ultrasound image segmentation using wavelet support vector machines. *Medical Physics*. 2012; 39:2972. [PubMed: 22755682]
11. Yang, X., et al. 3D non-rigid registration using surface and local salient features for transrectal ultrasound image-guided prostate biopsy. *SPIE Medical Imaging: Visualization, Image-Guided Procedures, and Modeling*. In: Wong, Kenneth N.; Holmes, David R., III, editors. Proceedings of SPIE. Vol. 7964. 2011. p. 79642V-1~8
12. Iczkourski KA, et al. Diagnosis of “suspicious for malignancy” in prostate biopsies: predictive value for cancer. *Urology*. 1998; 51:749.



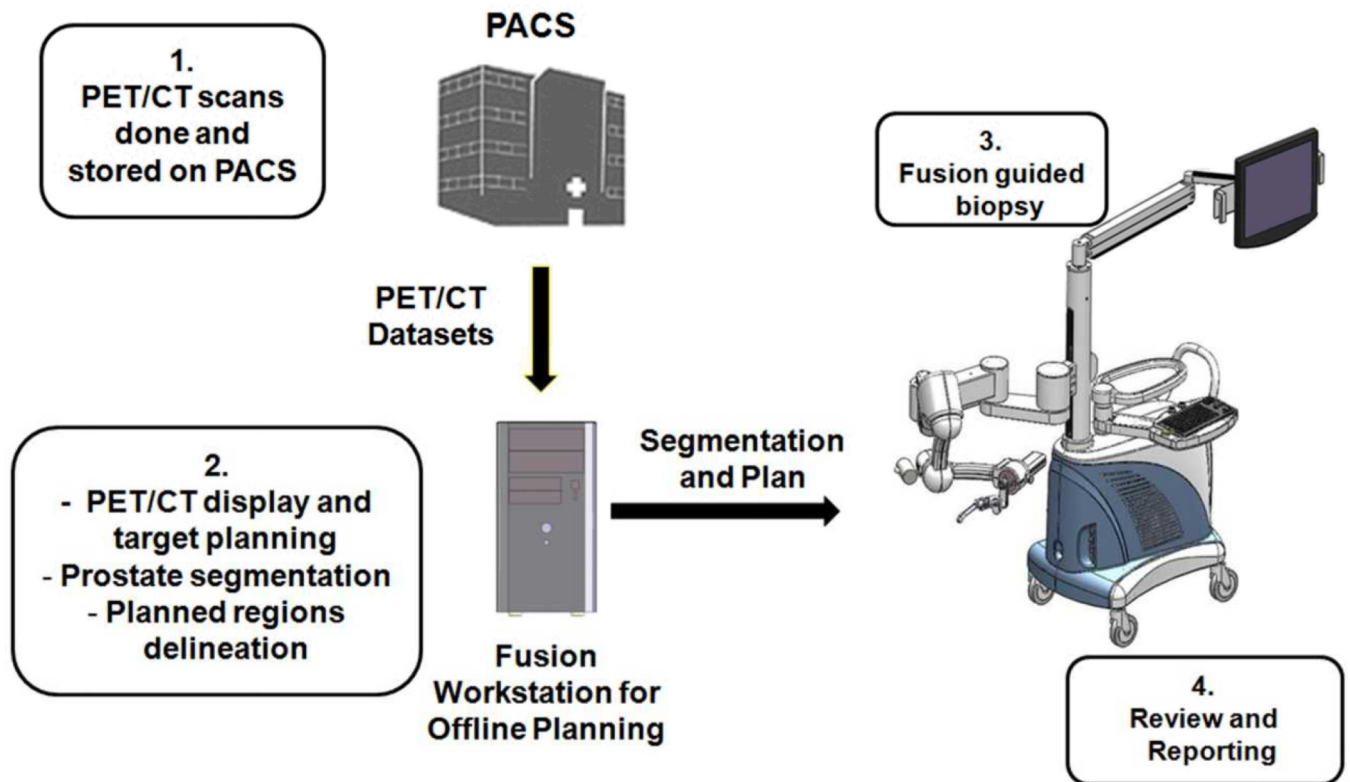
**FIGURE 1.**

Molecular image-directed, 3D ultrasound-guided biopsy. Top: PET/CT image using  $^{18}\text{F}$ -FACBC are acquired from a prostate patient. PET/CT images show a focal lesion within the prostate (white arrow). The 3D visualization of the pelvis and the prostate can be used to aid the insertion of the biopsy needle into a suspicious tumor target. Bottom: During biopsy, a mechanically assisted navigation device is used to acquire 3D TRUS images from patients. The prostate boundaries on TRUS images are segmented and used to generate a 3D model of the prostate. The 3D prostate model and real-time TRUS images are then used to guide the

biopsy in patients. (Image reprinted from Fei et al Proceedings of SPIE 2012, 8316, 831613-1-8).

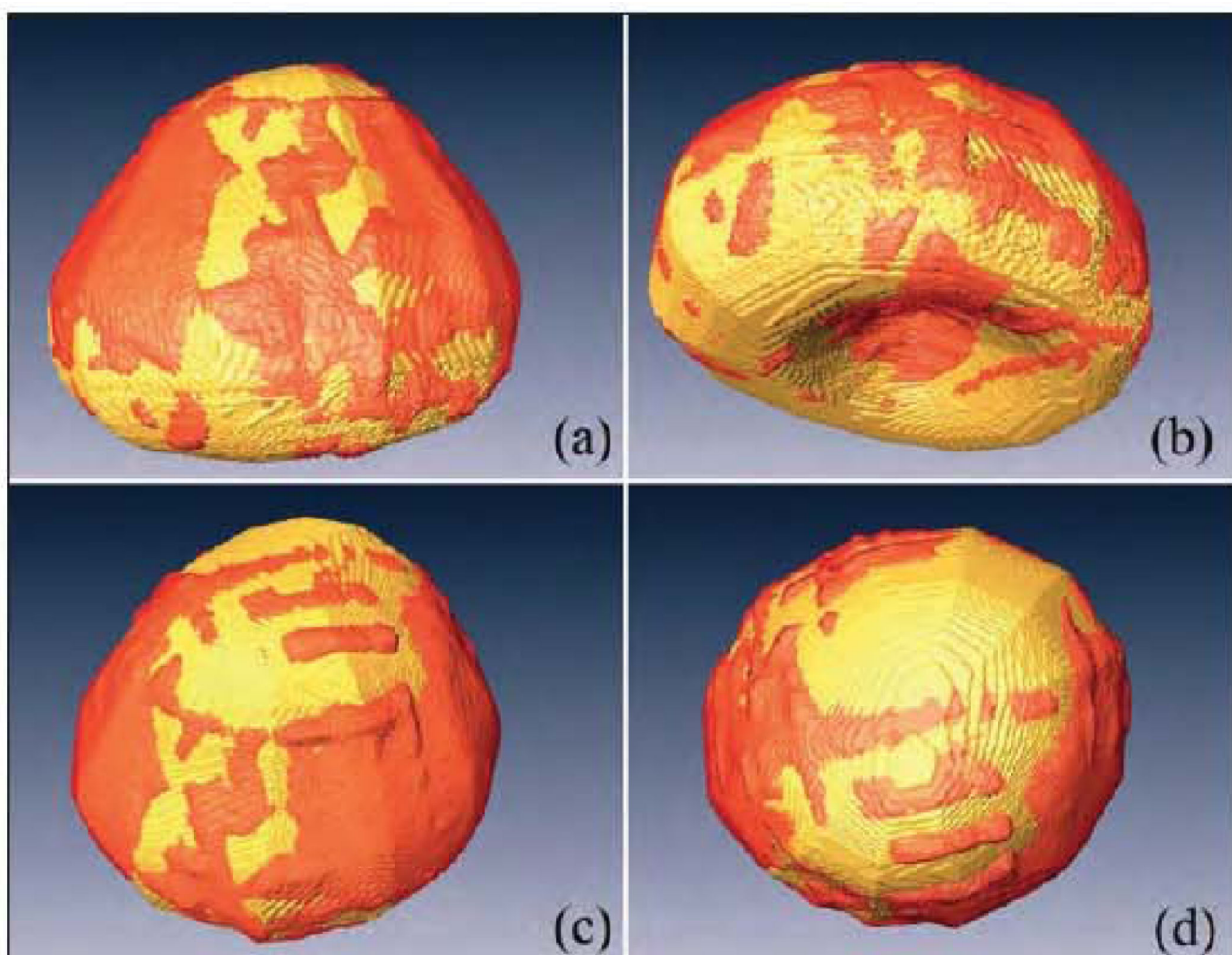


## Workflow for Targeted Biopsy



**FIGURE 2.**  
Workflow for the PET/ultrasound fusion guided biopsy system.





**FIGURE 3.**

Three-dimensional visualization of the segmented prostate (red) as compared to the manual gold standard (gold color) in four different views (a–d) of the same human prostate (Reprinted from Akbari and Fei, Medical Physics 2012; 39 :2972).